

The Saturn immediate load post extraction dental implant: a one year pilot study of 140 consecutive implants

Zvi Laster DMD, Sharif Araide DMD, Aaron Gonshor DDS, Daniel Baruch Eng.

The desire for immediate load restoration of dental implants, particularly in the anterior esthetic zone, requires specific implant design strategies to enhance primary stability. In the presence of extraction sites, often with compromised bone, implant fixation is obtained apically and palatally. Though surface roughness is a factor in early osseointegration the macro-architectural design of the implant establishes the initial mechanical fixation important for the first 3-4 weeks of function in order to minimize implant mobility.



Fig.1- Saturn- New "winged" design.

A new implant design, the Saturn dental implant (Cortex Dental Industries, Shlomi, Israel) ,employs a unique new strategy, that of extended sub-crestal threads, expanded out in a wing-like effect to engage socket walls mid-crestally for added primary stability (Figure 1+2).

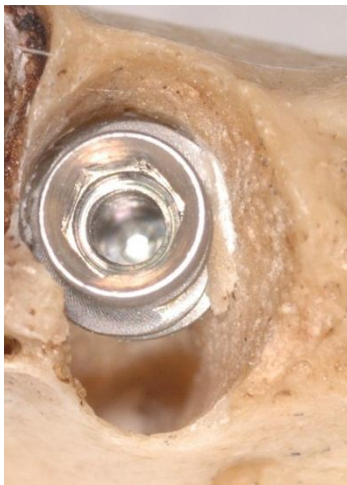

Fig.2- The extended "wing" engaging the corticalis of the socket`s wall.

The implant is a titanium grade 5 conical screw with internal hex suitable for immediate function. Two 2.4mm spiral channels with a thickened reverse buttress thread extends around the implant for vertical and horizontal bone compaction. Anti-rotational resistance is built into the thread design with a small platform switch for biological width. The

tapered form with deep threads is particularly well suited for maxillary bone and immediate function (Figure 3).

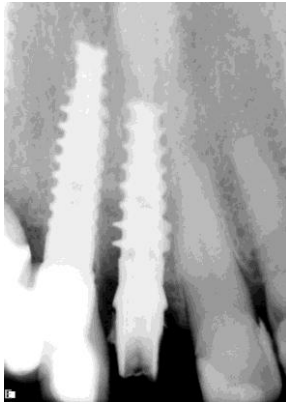


Fig.3- X-Ray demonstrates the extended "wing" engaging the corticalis of the socket`s wall.

Finite element analysis of the "winged" implant in compare to a regular implant revealed that when 20 Kg are applied at a 20 degrees , the amount of maximal displacement at the neck of a regular implant is 60% higher than the "winged" Saturn. (Fig.4)

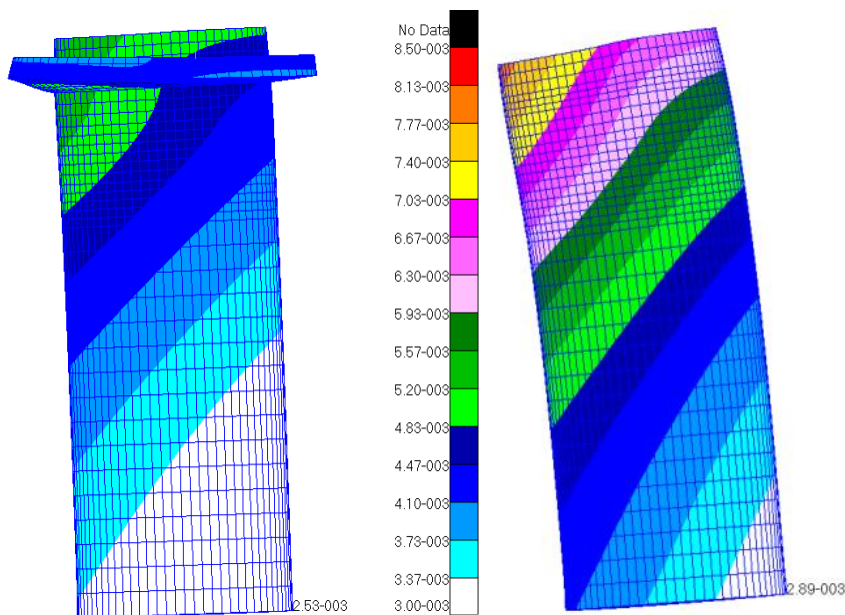


Fig.4- Max. displacement of the "Winged" implant is 5.2 mic. And 8.5 with the regular implant.

In order to evaluate the efficacy of this new implant a study was undertaken to evaluate the implant in both jaws under conditions of immediate function in the clinical setting.

Materials and Methods;

Three private clinics and the, Tiberias Medical Center, Upper Galilee Dental Center and the Department of Oral and Maxillofacial Surgery Poria governmental Hospital treated patients using the following selection criteria:

Bicuspid teeth and forward in the arch that required dental extraction and implant placement for immediate loading were selected for study. Patients were in general good health with no acute oral disease present.

Following dental extractions osseous wounds were debrided and implants placed on the palatal/lingual side of the sockets.

Bone was classified into four groups according to Zarb and Leukholm from Type I dense to Type IV low density cancellous bone. Insertion torque was then recorded. When insertion

torque was less than 35Ncm the implant was not loaded. Provisional restorations were to be fabricated and placed on the day of implant placement.

Case example;

A left lateral incisor was removed and implant placed at the palatal aspect of the socket (Figure 5).

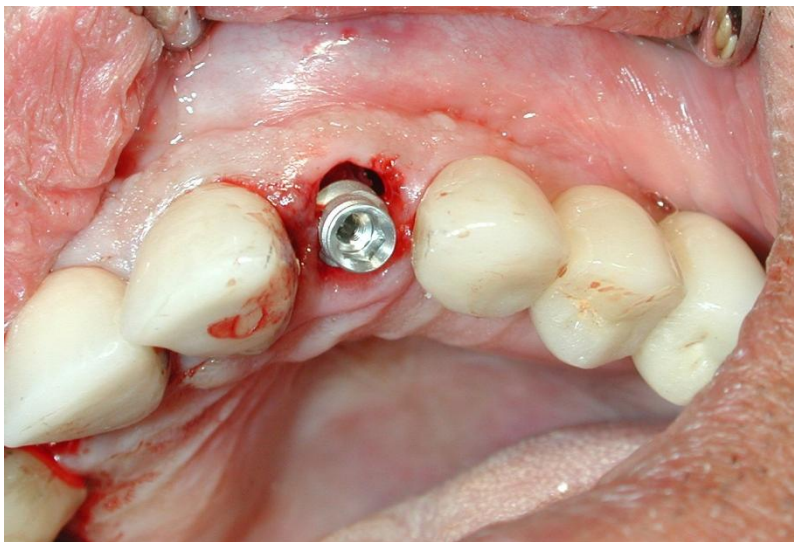


Fig.5- The Saturn is implanted into the extracted socket at palatal aspect.

Then seated into final position with a torque driver to 40Ncm (Figure 6).

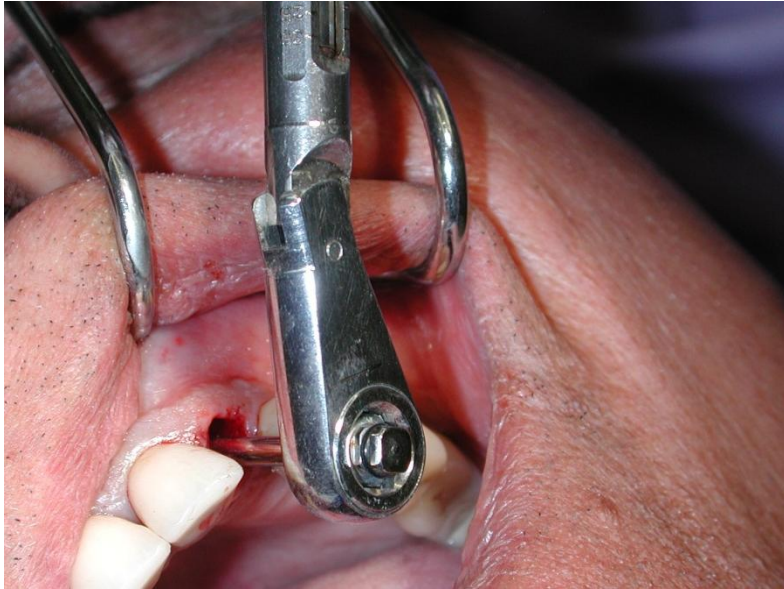

Fig.6- Final positioning with Torque Driver to over 40Ncm resistance.

The temporary abutment was then placed (Figure 7),

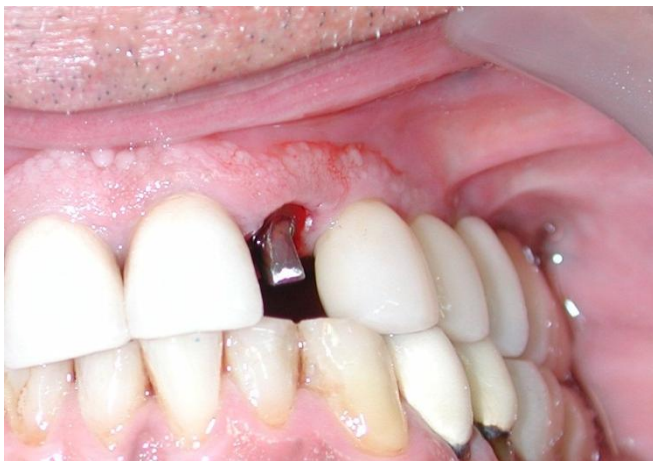

Fig.7- Temporary abutment is placed.

and the temporary crown cemented into place avoiding Occlusal contact (Figure 8).

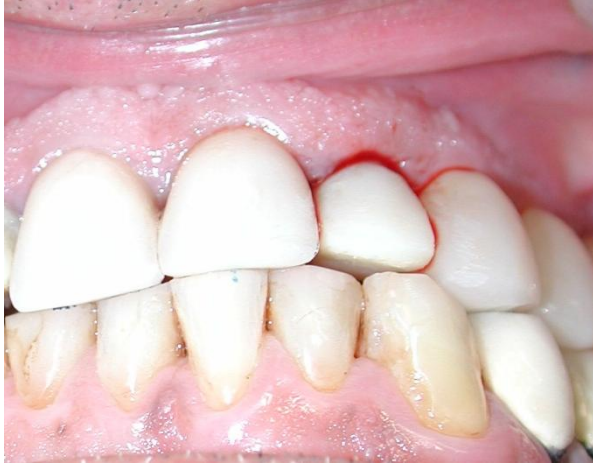

Fig.8- Temporary crown cemented avoiding Occlusal contact.

Figures 9,10 show the radiographic findings at the time of temporization and finalization after one year in function.

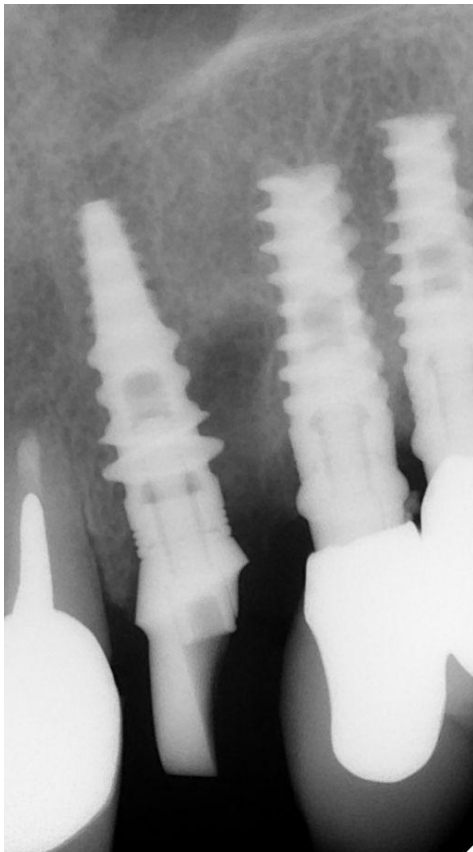


Fig.9- Post-Op x-ray on day of implantation.

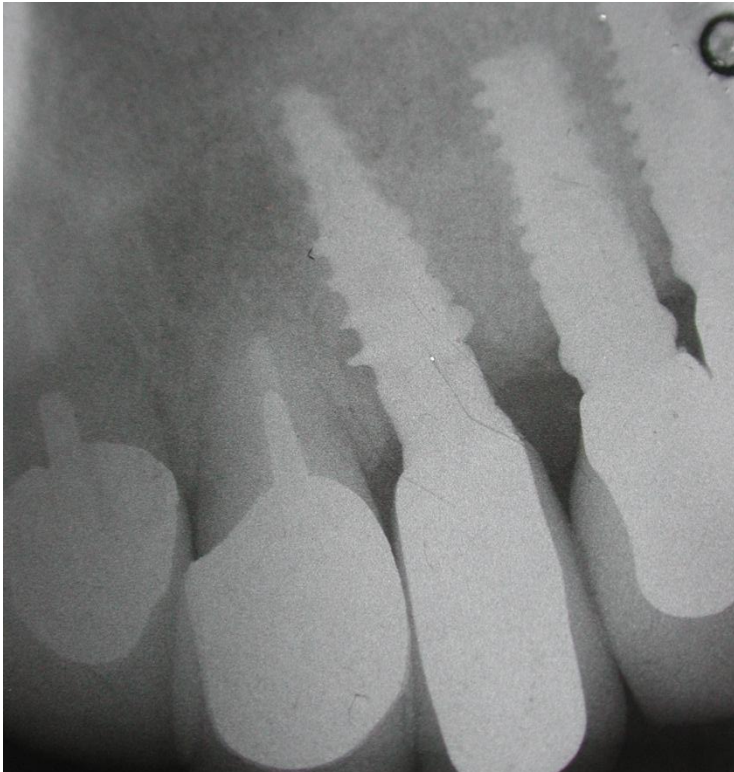


Fig.10- X-ray after one year in function.

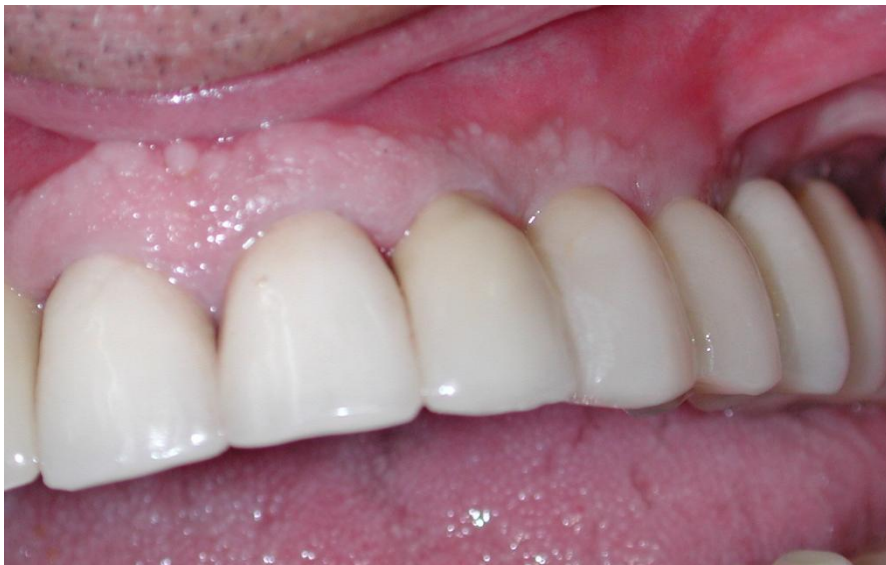

Fig.11- Final restoration after one year in function.

Results;

140 implants were placed consecutively over a one year period during 2009 and 2010. 95 implants were immediately loaded and 45 implants left submerged for staged loading. Of implants placed into immediate function, 83 were in the maxilla and 12 in the mandible.

Implants were examined at 1,6,12 and 16 weeks post placement and then proceeded to final restoration. There was a one year followed up. All implants were placed into functional occlusion and judged to be satisfactory esthetically. Five of the immediately loaded implants failed for a 3.6% failure rate.

All 40 submerged implants found to be osseointegrated (100%) on exposure and proceeded for final restoration.

Discussion;

The rationale for the use of an extended thread in the mid crestal location for extraction site stabilization is based on finite element analysis which demonstrates that in the presence of a winged thread pattern displacement of the implant, when measured at the neck, is reduced 40% under off-axis force (Figure 4). Therefore, non-axial loads, which are detrimental to

a fragile mechanical fixation, is buttressed by this design strategy.

Moreover, single root extraction site locations may engage bone earlier during the insertion of winged implant which helps to avoid deep implant placement in order to gain fixation.

Overall, the findings were favorable for the placement of the Saturn implant which proved particularly useful when bone was cancellous Type III or Type IV.

Besides this study , due to the high insertion resistance, the "winged" implant proved to be very useful in cases of open and closed sinus floor elevation, and at the tuberosity. The "winged " implant was also found to be very useful in cases of immediate replacement of failed implants, when initial stability is critical.

Conclusion

A pilot study of 140 consecutively placed Saturn dental implants followed up to one year after placement revealed a 96.4% implant success rate despite immediate loading in the presence of large extraction defects and poor quality bone.

These favorable preliminary findings must now be corroborated by longer term studies.

Bibliography;

1. Esposito M, Grusovin M, Polyzos I, Felice P, Worthington H. Interventions for replacing missing teeth: dental implants in fresh extraction sockets (immediate, immediate-delayed and delayed implants). Aust Dent J. 2011 Mar;56(1):100-2. doi: 10.1111/j.1834-7819.2010.01308.x.
- 2- Yamada K, Hoshina H, Arashiyama T, Arasawa M, Arai Y, Uoshima K, Tanaka M, Nomura S. Immediate implant loading following computer-guided surgery. J Prosthodont Res. 2011 Feb 4. [Epub ahead of print]
- 3- Javed F, Almas K, Crespi R, Romanos GE. Implant surface morphology and primary stability: is there a connection? Implant Dent. 2011 Feb;20(1):40-6.
- 4- Casap N, Laviv A, Wexler A. Computerized navigation for immediate loading of dental implants with a prefabricated metal frame: a feasibility study. J Oral Maxillofac Surg. 2011 Feb;69(2):512-9.
- 5- de Almeida EO, Filho HG, Goiatto MC. The use of transitional implants to support provisional prostheses during the healing phase: a literature review. Quintessence Int. 2011 Jan;42(1):19-24.
- 6- Bencharit S, Reside GJ, Howard-Williams EL Complex prosthodontic treatment with dental implants for a patient with polymyalgia rheumatica: a clinical report. Int J Oral Maxillofac Implants. 2010 Nov-Dec;25(6):1241-5.
- 7- Cooper LF, Raes F, Reside GJ, Garriga JS, Tarrida LG, Wiltfang J, Kern M, de Bruyn H. Comparison of radiographic and clinical outcomes following immediate provisionalization of single-tooth dental implants placed in healed alveolar ridges and extraction sockets. Int J Oral Maxillofac Implants. 2010 Nov-Dec;25(6):1222-32.
- 8- Siebers D, Gehrke P, Schliephake H. Delayed function of dental implants: a 1- to 7-year follow-up study of 222 implants. Int J Oral Maxillofac Implants. 2010 Nov-Dec;25(6):1195-202.
- 9- Degidi M, Nardi D, Piattelli A. Immediate loading of the edentulous maxilla with a definitive restoration supported by an intraorally welded titanium bar and tilted implants. Int J Oral Maxillofac Implants. 2010 Nov-Dec;25(6):1175-82.

- 10- Kim JH, Kim YK, Yi YJ, Yun PY, Lee HJ, Kim MJ, Yeo IS. Results of immediate loading for implant restoration in partially edentulous patients: a 6-month preliminary prospective study using SinusQuick™ EB implant system. J Adv Prosthodont. 2009 Nov;1(3):136-9. Epub 2009 Nov 30.
- 11- Slotte C, Lennerås M, Göthberg C, Suska F, Zoric N, Thomsen P, Nannmark U. Gene Expression of Inflammation and Bone Healing in Peri-Implant Crevicular Fluid after Placement and Loading of Dental Implants. A Kinetic Clinical Pilot Study Using Quantitative Real-Time PCR. Clin Implant Dent Relat Res. 2010 Nov 18. doi: 10.1111/j.1708-8208.2010.00309.x. [Epub ahead of print]
- 12- Kopp S, Kuzelka J, Goldmann T, Himmlova L, Ihde S. Modeling of load transmission and distribution of deformation energy before and after healing of basal dental implants in the human mandible. Biomed Tech (Berl). 2011 Feb;56(1):53-8. Epub 2010 Nov 17.
- 13- Jensen OT, Adams MW, Cottam JR, Parel SM, Phillips WR 3rd. The all on 4 shelf: mandible. J Oral Maxillofac Surg. 2011 Jan;69(1):175-81. Epub 2010 Nov 4.
- 14- Peñarrocha-Diago MA, Maestre-Ferrín L, Demarchi CL, Peñarrocha-Oltra D, Peñarrocha-Diago M. Immediate versus nonimmediate placement of implants for full-arch fixed restorations: a preliminary study. J Oral Maxillofac Surg. 2011 Jan;69(1):154-9. Epub 2010 Nov 2.
- 15- Liñares A, Mardas N, Dard M, Donos N. Effect of immediate or delayed loading following immediate placement of implants with a modified surface. Clin Oral Implants Res. 2011 Jan;22(1):38-46. doi: 10.1111/j.1600-0501.2010.01988.x. Epub 2010 Oct 6.
- 16- Hasan I, Heinemann F, Aitlahrach M, Bourauel C. Biomechanical finite element analysis of small diameter and short dental implant. Biomed Tech (Berl). 2010 Dec;55(6):341-50. Epub 2010 Oct 28.
- 17- Shibly O, Kutkut A, Patel N, Albandar JM. Immediate Implants with Immediate Loading vs. Conventional Loading: 1-Year Randomized Clinical Trial. Clin Implant Dent Relat Res. 2010 Oct 26. doi: 10.1111/j.1708-8208.2010.00310.x. [Epub ahead of print]
- 18- Francetti L, Romeo D, Corbella S, Taschieri S, Del Fabbro M. Bone Level Changes Around Axial and Tilted Implants in Full-Arch Fixed Immediate Restorations. Interim Results of a Prospective Study. Clin Implant Dent Relat Res. 2010 Oct 26. doi: 10.1111/j.1708-8208.2010.00304.x. [Epub ahead of print]
- 19- Götz W, Gedrange T, Bourauel C, Hasan I. Clinical, biomechanical and biological aspects of immediately loaded dental implants: a critical review of the literature. Biomed Tech (Berl). 2010 Dec;55(6):311-5. Epub 2010 Oct 25.

- 20- Heinemann F, Hasan I, Schwahn C, Biffar R, Mundt T. Crestal bone resorption around platform-switched dental implants with fine threaded neck after immediate and delayed loading. Biomed Tech (Berl). 2010 Dec;55(6):317-21. Epub 2010 Oct 25.
- 21- Kacer CM, Dyer JD, Kraut RA. Immediate loading of dental implants in the anterior and posterior mandible: a retrospective study of 120 cases. J Oral Maxillofac Surg. 2010 Nov;68(11):2861-7.
- 22- Covani U, Marconcini S, Santini S, Cornelini R, Barone A. Immediate restoration of single implants placed immediately after implant removal. A case report. Int J Periodontics Restorative Dent. 2010 Dec;30(6):639-45.
- 23- Avvanzo P, Fabrocini L, Avvanzo A, Ciavarella D, Lo Muzio L, Raffaele DM. Use of intra-oral welding to stabilize dental implants in augmented sites for immediate provisionalization: a case report. J Oral Implantol. 2010 Oct 8. [Epub ahead of print]
- 24- Bansal DJ, Kedige DS, Bansal DA, Anand DS. A Relaxed Implant Bed: Implants Placed After Two Weeks of Osteotomy with Immediate Loading- A One Year Clinical Trial. J Oral Implantol. 2010 Oct 6. [Epub ahead of print]
- 25- Pae A, Kim JW, Kwon KR. Immediate loading of two implants supporting a magnet attachment-retained overdenture: one-year clinical study. Implant Dent. 2010 Oct;19(5):428-36.
- 26- Roe P, Kan JY, Rungcharassaeng K, Lozada JL, Kleinman AS, Goodacre CJ, Chen JW. Immediate loading of unsplinted implants in the anterior mandible for overdentures: a case series. Int J Oral Maxillofac Implants. 2010 Sep-Oct;25(5):1028-35.
- 27 Hinze M, Thalmair T, Bolz W, Wachtel H.- Immediate loading of fixed provisional prostheses using four implants for the rehabilitation of the edentulous arch: a prospective clinical study. Int J Oral Maxillofac Implants. 2010 Sep-Oct;25(5):1011-8.
- 28- Park EJ, Schrott A, Schnitman PA. Immediate loading as a vehicle for interdisciplinary training in implant placement and restoration. Int J Oral Maxillofac Implants. 2010 Sep-Oct;25(5):1007-10.
- 29- Capelli M, Esposito M, Zuffetti F, Galli F, Del Fabbro M, Testroi T. A 5-year report from a multicentre randomised clinical trial: immediate non-occlusal versus early loading of dental implants in partially edentulous patients. Eur J Oral Implantol. 2010 Autumn;3(3):209-19.

30- Esposito M, Grusovin MG, Polyzos IP, Felice P, Worthington HV. Timing of implant placement after tooth extraction: immediate, immediate-delayed or delayed implants? A Cochrane systematic review. Eur J Oral Implantol. 2010 Autumn;3(3):189-205. Review.